

CASE REPORT

Mandibular bone necrosis caused by use of arsenic paste during endodontic treatment: two case reports

M. S. Yavuz, G. Şimşek Kaya, E. Yalçın & M. H. Aras

Department of Oral and Maxillofacial Surgery, Faculty of Dentistry, Atatürk University, Erzurum, Turkey

Abstract

Yavuz MS, Şimşek Kaya G, Yalçın E, Aras MH. Mandibular bone necrosis caused by use of arsenic paste during endodontic treatment: two case reports. *International Endodontic Journal*, **41**, 633–637, 2008.

Aim To report that arsenical pastes are still employed in endodontics and to highlight the potentially serious consequences of their use.

Summary Chemotherapeutic agents such as arsenic trioxide and paraformaldehyde were once commonly employed as pulp-necrotizing agents. Their cytotoxic effects are well recognized, and leakage from teeth has been associated with widespread necrosis of periodontal tissues and bone. This report describes two cases of severe bone necrosis affecting the mandible following the use of an arsenical paste.

Key learning points

- Pulp-necrotizing agents such as arsenic trioxide can cause severe bone necrosis.
- Arsenical pastes have no place in contemporary dental practice.
- Dentists should employ appropriate local anaesthetic techniques for pulp extirpation instead of relying on toxic necrotizing agents.

Keywords: arsenic, arsenic trioxide, endodontic treatment, mandible, necrosis.

Received 24 August 2006; accepted 23 January 2008

Introduction

The history of arsenic trioxide in endodontic treatment began with Haly Abbas in 1492 (cited by Smart & Barnes 1991). The agent was widely accepted after Spooner described the use of arsenic trioxide for devitalization of the pulp in 1836 (cited by Bataineh *et al.* 1997, Cruse & Bellizzi 1980).

Because of the potential for leakage, the use of arsenic oxide for devitalizing pulp was always unsafe. For this reason, and after improvements in local anaesthesia, the use of

Correspondence: Dr M. Selim Yavuz, Department of Oral and Maxillofacial Surgery, Faculty of Dentistry, Atatürk University, 25240 Erzurum, Turkey (Tel.: +90 442 2311734; fax: +90 442 2360945; e-mail: mselimyavuz@gmail.com).

arsenical 'devitalizing pastes' gradually declined (Bataineh *et al.* 1997, Yalcin *et al.* 2003, Garip *et al.* 2004).

Arsenic and its compounds are known to be extremely toxic on contact with hard and soft tissues, and prolonged application or leakage of arsenic trioxide can cause severe damage to the periodontal tissues and alveolar bone; osteomyelitis of the jaws has also been described (Yakata *et al.* 1985, Bataineh *et al.* 1997, Chim *et al.* 2002, Yalcin *et al.* 2003, Garip *et al.* 2004, Dumlu *et al.* 2007). Despite such reports, serious complications following the use of arsenicals, continue to be described, even in developed countries (Smart & Barnes 1991, Bataineh *et al.* 1997, Ozmeric 2002).

This article describes two cases in which arsenical pulp devitalization in mandibular molar teeth was associated with significant hard and soft tissue injury.

Case reports

Case 1

A 38-year-old woman was referred in October 2004 to Ataturk University, Faculty of Dentistry, Department of Oral and Maxillofacial Surgery complaining of constant pain and oedema of the right cheek. The history confirmed that her dentist had applied an arsenic paste to tooth 46 pulp during root canal treatment because of unsuccessful local anaesthesia. The next day, the patient experienced severe and increasing pain and the dentist extracted tooth 46 at her second appointment. However, the patient's complaints did not resolve, and the dentist recommended her to consult with a specialist. On presentation, a sequestrum affecting the second premolar at the extraction site was noted. Panoramic radiography revealed a radiolucent area in the tooth 46 and 45 region (Fig. 1). Further treatment included the removal of tooth 45 and localized sequestrectomy under local anaesthesia (Fig. 2). Primary closure of the wound was secured with a 3-0 silk suture. A course of oral amoxicillin trihydrate 825 mg plus potassium clavulanate 125 mg was given twice a day for 10 days. Additionally, the patient received oral naproxen sodium 550 mg as an analgesic and chlorhexidine gluconate as a mouthwash two times a day for 5 days. A soft diet was advised during the first postoperative week, and the patient was recalled to evaluate healing. Although the clinical examination confirmed painless healing, a panoramic radiograph

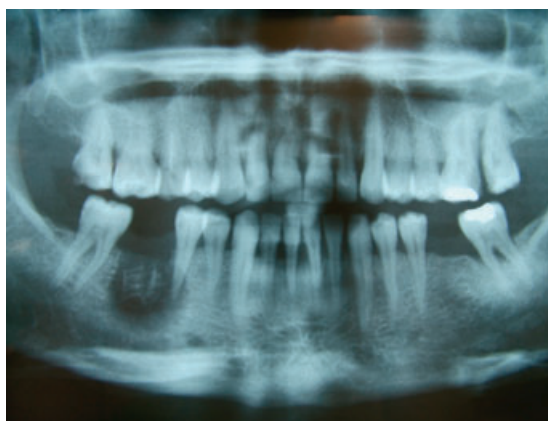

Figure 1 Panoramic radiograph showing an extensive bony radiolucency in teeth 46 and 45.

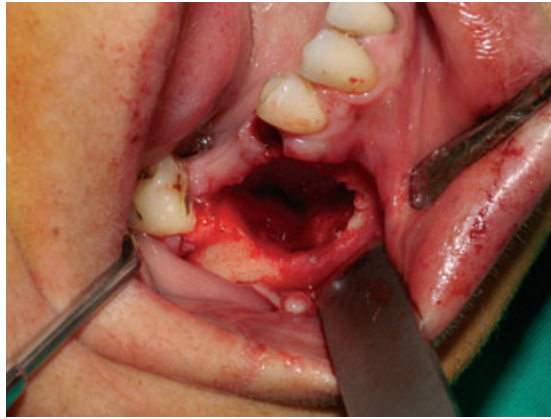


Figure 2 Healthy bone surface after removal of necrotic tissue.

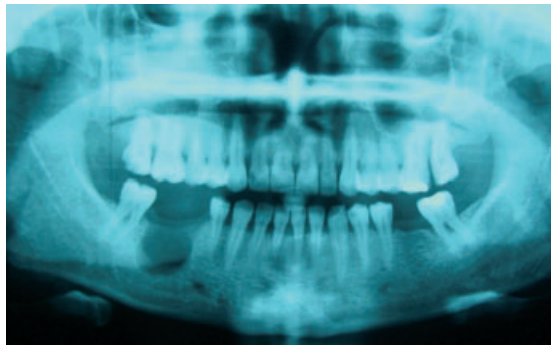

Figure 3 Orthopantomograph showing a persistent bony defect although the patient was asymptomatic.

showed bony healing in the 45 region but a substantial, persistent bony lucency in the 46 area (Fig. 3).

Case 2

A 49-year-old woman was referred because of intense pain following the extraction of tooth 36. The history revealed that a dentist had undertaken root canal treatment on the tooth with an arsenical paste 2 months previously. After the first appointment, the patient explained that an intense pain had started in the area. Because of unabated pain, the patient decided to have the tooth extracted. Clinically, there was tissue necrosis, and alveolitis in the extraction area. A panoramic radiograph revealed a radiopaque mass enclosed within a radiolucent line in the extraction area (Fig. 4). In the light of the history, clinical and radiographic findings, chemical necrosis of the mandible was diagnosed, and the area was surgically explored under local anaesthesia. Sequestrectomy was performed, and primary closure was secured. The follow-up period was uneventful. At the tenth month, healing had progressed well clinically (Fig. 5). Although some loss of the alveolar bone had occurred, bone healing was satisfactory at the tenth month (Fig. 6).

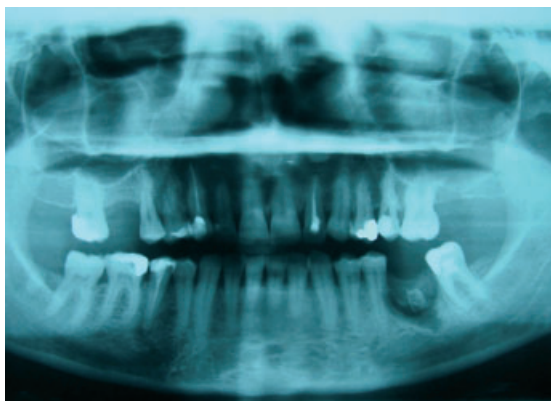


Figure 4 Preoperative radiographic appearance of case 2.

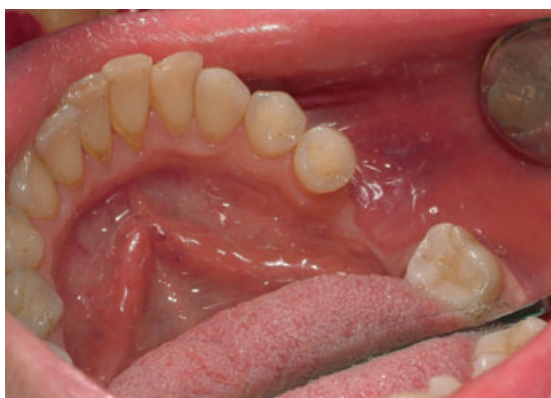

Figure 5 Intraoral appearance of operation site at 10 months.

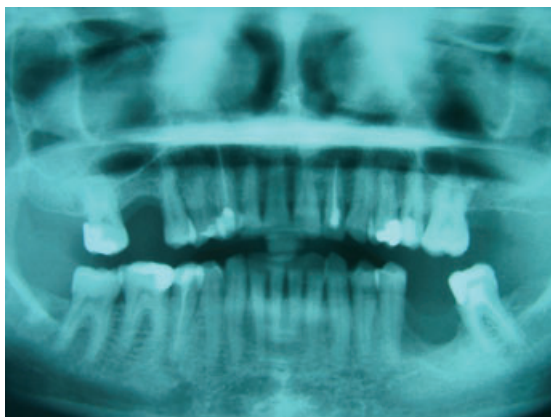

Figure 6 Radiographic appearance of 36 region at 10 months.

Discussion

In the past, local anaesthesia was less reliable and the use of devitalizing pastes became established practice (Ozmeric 2002). However, arsenic and its compounds are extremely

toxic and potentially carcinogenic when they are in contact with hard and soft tissues. Despite its hazardous effects, arsenic has been recommended in strictly controlled doses in the treatment of diseases such as solid tumours, multiple myeloma and acute promyelocytic leukaemia but not for endodontic purposes (Garip *et al.* 2004). Nevertheless, cases of arsenic-related tissue necrosis are still reported, especially in developing countries (Ozmeric 2002, Yalcin *et al.* 2003, Garip *et al.* 2004, Ozgoz *et al.* 2004).

Yakata *et al.* (1985) described such a case with extensive bony destruction affecting not only the involved teeth, but also the entire ascending ramus of the mandible, which was surgically removed. Similarly, Yalcin *et al.* (2003) reported a case with a bilateral oroantral fistula that resulted from the leakage of an arsenic trioxide paste from the pulp chamber of endodontically treated teeth. Bataineh *et al.* (1997) reported mandibular bone necrosis following the use of arsenic paste.

In all cases of arsenic-induced bone necrosis, sequestrectomy is the only treatment option. After such treatment, loss of the alveolar bone and/or attached gingiva is unavoidable, and may create further ongoing dental problems.

Conclusion

Arsenic compounds have no place in endodontic practice and should be banned worldwide.

Disclaimer

Whilst this article has been subjected to Editorial review, the opinions expressed, unless specifically indicated, are those of the author. The views expressed do not necessarily represent best practice, or the views of the IEJ Editorial Board, or of its affiliated Specialist Societies.

References

- Bataineh AB, Al-Omari MA, Owais AI (1997) Arsenical necrosis of the jaws. *International Endodontic Journal* **30**, 283–7.
- Chim CS, Lam CC, Wong KF, Man C, Kam S, Kwong YL (2002) Atypical blasts and bone marrow necrosis associated with near-triploid relapse of acute promyelocytic leukemia after arsenic trioxide treatment. *Human Pathology* **33**, 849–51.
- Cruse WP, Bellizzi R (1980) A historic review of endodontics, 1689–1963, part 1. *Journal of Endodontics* **6**, 495–9.
- Dumlu A, Yalcinkaya S, Olgac V, Guvercin M (2007) Osteomyelitis due to arsenic trioxide use for tooth devitalization. *International Endodontic Journal* **40**, 317–22.
- Garip H, Salih IM, Sener BC, Goker K, Garip Y (2004) Management of arsenic trioxide necrosis in the maxilla. *Journal of Endodontics* **30**, 732–6.
- Ozgoz M, Yagiz H, Cicek Y, Tezel A (2004) Gingival necrosis following the use of a paraformaldehyde-containing paste: a case report. *International Endodontic Journal* **37**, 157–61.
- Ozmeric N (2002) Localized alveolar bone necrosis following the use of an arsenical paste: a case report. *International Endodontic Journal* **35**, 295–9.
- Smart ER, Barnes IE (1991) Tissue necrosis after using an arsenical endodontic preparation: a case report. *International Endodontic Journal* **24**, 263–9.
- Yakata H, Azumi T, Kawasaki T, Nakajima T (1985) Extensive osteolysis of the mandible following devitalization of a tooth by arsenic trioxide: a case report. *Journal of Oral Maxillofacial Surgery* **43**, 462–6.
- Yalcin S, Aybar B, Haznedaroglu F, Yucel E (2003) Bilateral oroantral fistulas following devitalization of teeth by arsenic trioxide: a case report. *Journal of Endodontics* **29**, 205–7.